



# Hypoglycemia in Non-Diabetic Patient: Report of Two Cases of Insulinoma

Evis Adriana Castellón De la Rosa,<sup>1</sup> Christian Pérez Calvo,<sup>2\*</sup> Luisa Fernanda Jiménez Arcia,<sup>1</sup> Estiven Crespo Vizcaino,<sup>1</sup> Carlos José Brito Jacome,<sup>1</sup> Raquel Cano Peñaloza,<sup>3</sup> Valentina Marrugo Padilla,<sup>4</sup> Luis Francisco Saray Ricardo,<sup>1</sup> Gabriel Padilla Vega<sup>1</sup>

<sup>1</sup>Resident 3<sup>rd</sup> year of Internal Medicine, Libre University, Colombia

<sup>2</sup>Resident 1<sup>st</sup> year of Internal Medicine, Libre University, Colombia

<sup>3</sup>Clínica General del Norte Organization, Barranquilla, Colombia

<sup>4</sup>Medical student, University of Cartagena; Research Group, Colombia

## Abstract

**Background:** Insulinoma is a B-cell tumor of the islets of the pancreas with an incidence of 4 per 1 million people per year, which produces excess insulin and can cause symptoms related to hypoglycemia at the level of the central nervous system or symptoms related to excess release of compensatory catecholamines. The presence of hypoglycemia, elevated insulin, proinsulin, and c-peptide levels suggest endogenous hyperinsulinism, which together with imaging findings suggestive of neuroendocrine tumor, allow establishing the diagnostic impression of Insulinoma.

**Cases report:** Patients with neuroglycopenic symptoms, biochemical profile of hypoglycemia, endogenous hyperinsulinemia and radiological finding compatible with insulinoma are reported, who were treated by surgical resection of the tumor, with complete resolution of the initial symptoms.

**Conclusion:** The clinical presentation, diagnosis and treatment of insulinoma represents a clinical challenge, since it is a rare pathology and the delay in diagnosis can have catastrophic consequences for the patient, stories such as permanent brain damage and death.

**Keywords:** Pancreas, Hyperinsulinism, Insulinoma, Hypoglycemia, Tumor, Neurosecretory systems

## Introduction

Insulinoma is a B-cell tumor of the islets of the pancreas with an incidence of 4 per 1 million people a year, which produces excess insulin and may cause symptoms related to hypoglycemia in the central nervous system or symptoms related to excess release of

compensating catecholamines.<sup>1,2</sup> The presence of hypoglycemia, elevated insulin levels, proinsulin and peptide c suggest endogenous hyperinsulinism, in addition to imaging findings suggestive of neuroendocrine tumor, allow establishing the diagnostic impression of insulinoma.<sup>3</sup>

Quick Response Code:



\*Corresponding author: Christian Pérez Calvo, Km 7 Antigua via Puerto Colombia, Barranquilla, Colombia

Received: 17 June, 2022

Published: 11 July, 2022

Citation: Rosa EACD, Calvo CP, Arcia LFJ, Vizcaino EC, Jacome CJB, et al. Hypoglycemia in Non-Diabetic Patient: Report of Two Cases of Insulinoma. *SOJ Med Clin Case Rep.* 2022;2(1):1-5. DOI: [10.53902/SOJMCCR.2022.02.000513](https://doi.org/10.53902/SOJMCCR.2022.02.000513)

## Case Submission

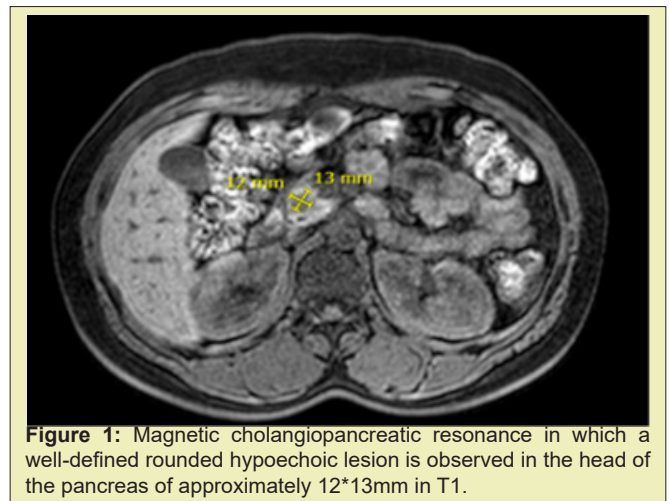
### Case 1

A 27-year-old woman admitted to a health institution in the city of Barranquilla for blurred vision, altered mental status, asthenia, cryo-dysphoresis and episodes of palpitations. The patient reported that nine months before the consultation she was asymptomatic, however; her mother began to observe unusual behaviors described below. During the first episode the patient presented blurred vision associated with incoherent speech, symptoms that were resolved after food intake, but she refers not to remember the details of the medical event. This was repeated during the first four months with a frequency of one to two times per week, which subsequently progressed to appear in shorter intervals of time with predominance in the morning hours. One day before admission, the patient's mother observed that she presented similar symptoms to those of previous episodes, so she is taken to the emergency department of the health institution for evaluation. Upon admission, the patient denied personal pathological history, consumption of hypoglycemic drugs or insulin secretagogues, as well as consumption of alcoholic beverages. In addition, he denied any family history of cardiac, renal or autoimmune pathologies.

On physical examination, blood pressure of 120/70mmHg, regular heart rate of approximately 95lpm and respiratory rate of 16rpm, with peripheral oxygen saturation of 96% in ambient air, body mass index of 22.9kg/m<sup>2</sup>, hydrated, rhythmic cardiac noises, without respiratory aggregates; at neurological examination with evidence of neuroglycopenic, adrenergic and cholinergic signs, glucometry is documented in 41mg/dL, in relation to symptomatic hypoglycemia, a baseline confirmatory test was requested and a 10% (25g) HPD bolus was indicated with symptom resolution, configuring a positive Whipple triad, so a 72-hour fasting test was omitted. In addition, paraclinics were ordered to confirm endogenous hyperinsulinism, with the following results: central glycemia: 41mg/dl (70-110mg/dL), free insulin: 30.42pmol/L (2.9-18pmol/L), C peptide: 4.03nmol/L (1.1-4.4nmol/L), proinsulin: 7.6pmol/L (5pmol/L), confirming diagnostic suspicion; in addition intact PTH report: 28.07pg/mL (7.5-53.5pg/mL), total calcium: 8.3mg/dL (8-10mg/dL), baseline prolactin: 14 (4-15.2), cortisol Am: 6.91mcg/dL (4.82-19.5mcg/dL), cortisol Pm 5.16mcg/dL (2.47-11.9mcg/dL) which were found within reference parameters discarding multiple endocrine neoplasia type 1 associated MEN-1.

When neuroendocrine tumor causing endogenous hyperinsulinism is suspected, a CT scan of the abdomen is performed, which was reported as normal in this case and endosonography showed a well-defined rounded hypoechoic lesion of approximately 12\*13mm in the head of pancreas. ACAF was performed with suggestive report of neuroendocrine neoplasia. Localization study

is complemented with magnetic cholangio pancreato resonance Figure 1 and defined as a candidate for surgical management type enucleation of the lesion. The biopsy reported well-differentiated neuroendocrine tumor of 1.3\*1.2cm, 2 mitoses in 10 high-power fields, without evident tumor necrosis, lymphovascular invasion or perineural invasion. Lymph node negative for malignancy. The patient evolved appropriately during the postoperative period, without presenting new episodes of symptomatic hypoglycemia.



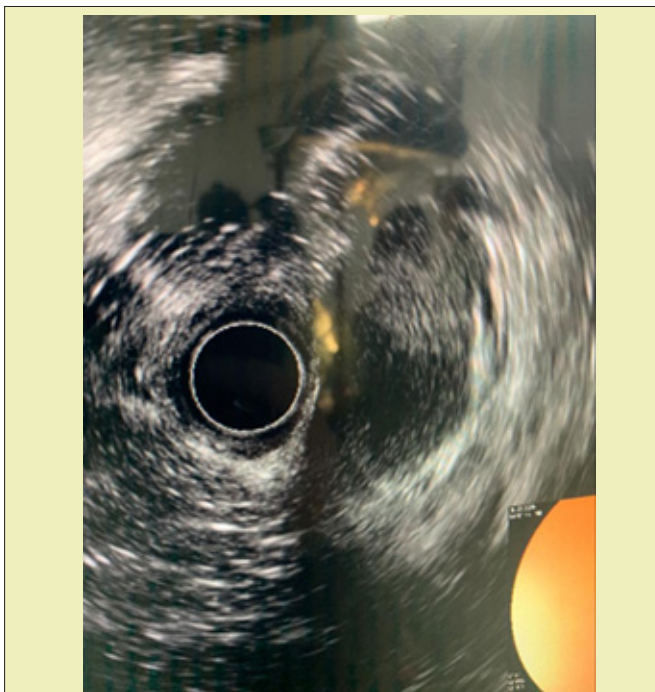**Figure 1:** Magnetic cholangiopancreatic resonance in which a well-defined rounded hypoechoic lesion is observed in the head of the pancreas of approximately 12\*13mm in T1.

### Case 2

A 36-year-old woman with a two-year history of dizziness, profuse sweating, decreased muscle strength and syncope, which improved after food administration, requiring repeated visits to the emergency department, in which low blood glucose levels are shown during these events. The patient was in follow-up by the endocrinology service two months earlier, where she was asked to perform paraclinics in the presence of Whipple triad, documenting the following findings: fasting glycemia: 38mg/dL low, insulin: 25.03pmol/L (2,9-18pmol/L) elevated, proinsulin: 6.5pmol/L (5pmol/L) elevated, peptide C: 1,63nmol/L (1.1-4.4nmol/L), PTH: 26pg/mL (7,5-53,5pg/mL) and prolactin: 22ng/ml, the latter within normal parameters. Additionally, biliopancreatic endosonography was performed with a reported hyperechoic lesion of 16.3\*9.2mm in diameter in the pancreatic neck, sparingly vascularized without adenopathies, with alteration in homogeneity in the pancreas due to poor lobulations, with pathological report of well-differentiated epithelial neoplasia possibly neuroendocrine.

In addition, with an MRI report in which lesion was observed with an uncinete process suggestive of insulinoma with 16 mm in diameter in the neck of the pancreas, so admission to the health institution was decided for follow-up and case management. During her stay the patient is evaluated by hepatobiliary surgery service, who requests verified magnetic resonance cholangio resonance in which no tumor-like lesions in the pancreas were identified. Addi-

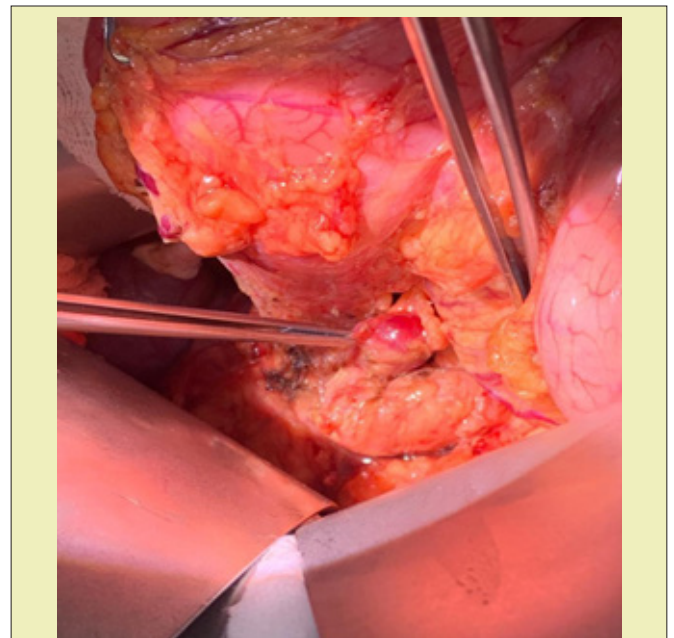
tionally, it requests biliopancreatic endosonography with the result of 18mm diameter hypoechoic lesion dependent on the head of the pancreas in its posterior and inferior aspect to the right of the mesenteric vein, dynamic pancreatic angiogram is also performed without evidence of focal lesions or abnormal reinforcements. After imaging findings without clear documentation of the location of the lesion, intraoperative endosonography is decided Figure 2 and subsequent enucleation of the pancreatic tumor Figures 3 and 4. The biopsy report concluded: well-differentiated epithelial neoplasia with neuroendocrine origin category IV and the immunohistochemical report showed grade 2 neuroendocrine neoplasia (WHO 2017) with immunohistochemical insulinoma profile. The patient evolved satisfactorily after the surgical procedure and has not presented new episodes of symptomatic hypoglycemia.



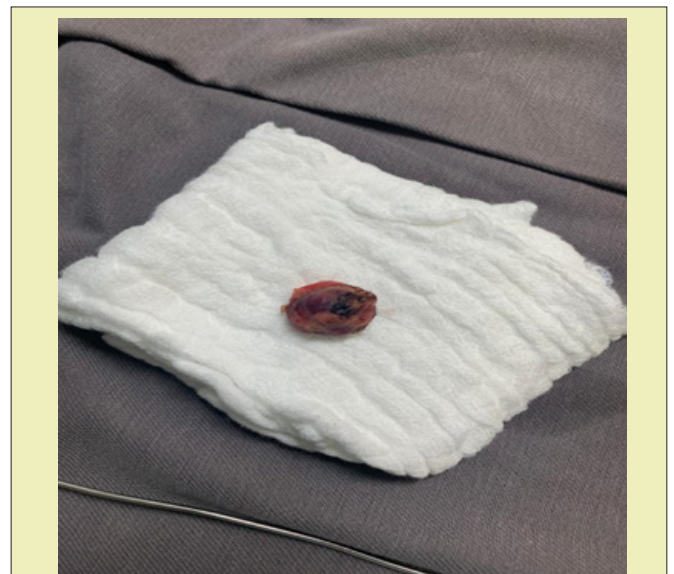**Figure 2:** High-frequency intraoperative biliopancreatic endoscopic ultrasound, in which pancreatic parenchyma is observed with alteration of echogenicity in the head of the pancreas given by homogeneous lobed hypoechoic lesion with well-defined edges measuring 13mm.

## Discussion

Insulinoma is a rare tumor of the pancreas that occurs 4 per 1 million people a year. Among the causes of endogenous hyperinsulinism is the most common, evidenced in approximately 55% of cases in adults.<sup>2</sup> It can occur at any age, with an equitable gender distribution. 90% of the cases are benign, solitary, of diameter <2cm and more than 90% are intrapancreatic. Extra pancreatic are usually located in the duodenal wall and may occur sporadically or be associated with multiple endocrine neoplasia type 1 (MEN-1).<sup>3,4</sup>



**Figure 3:** Prior to insulinoma enucleation. Hyper vascularized nodular lesion of neuroendocrine appearance of pancreatic tissue is observed in head of pancreas of approximately 13mm.



**Figure 4:** Surgical piece. Macroscopic sample of head insulinoma of the pancreas is shown.

Insulinoma is characterized clinically by the appearance of hypoglycemia, which must be confirmed by the Whipple triad consisting of:

- 1) Symptoms, signs or both compatible with hypoglycemia
- 2) A low plasma glucose concentration determined by a reliable method
- 3) The disappearance of these symptoms and signs once the plasma glucose concentration is restored.<sup>5</sup>



Symptomatic hypoglycemia can occur with different manifestations including neuroglucopenic as cognitive abnormalities, behavioral changes, psychomotor alteration and adrenergic manifestations such as tremors, palpitations, anxiety or cholinergic as sweating, hunger, given as a result of excess release of compensating catecholamines.<sup>5</sup>

The first step in the study of the patient with hypoglycemia is to differentiate whether the presence of symptomatic hypoglycemia is associated with diabetes mellitus or not. In non-associated cases, drug consumption, alcohol, autoimmune pathologies, critical, auto-inflammation should be investigated. In apparently healthy individuals, the presence of low levels of glycemia, elevated insulin levels, proinsulin, C peptide suggest endogenous hyperinsulinism, and imaging findings suggestive of neuroendocrine tumor, allow the diagnostic impression of insulinoma to be established.

In this review, 2 cases of apparently healthy patients with manifestations of symptomatic hypoglycemia are reported in the absence of a history of alcohol consumption, secretory drugs or findings that indicate in the first instance a critical or autoimmune disease.

In the absence of spontaneous hypoglycemia, the fasting test, which is the gold standard to confirm hypoglycemia, is used.<sup>6,7</sup> Serum insulin documentation greater than 3mU/ml, C peptide greater than 0,2nmol/L (0,6ng/ml) and proinsulin greater than 5pmol/L, in the absence of any circulating hypoglycemic agent and negative insulin antibodies during the episode indicate a process of endogenous hyperinsulinism.<sup>6</sup> In the cases reported in this review, the fasting test was not necessary since hypoglycemia was spontaneously documented. Hypoglycemic drug levels were not measured because they did not report a history of sulfonylurea consumption, glinides or insulin and no antibodies to insulin or antibodies to insulin receptors were measured due to the absence of a history suggesting autoimmune disease. In the first case, elevated levels of C peptide, proinsulin, and insulin were reported, and in the second case, with the exception of the C peptide (within the reference range), they were also elevated.

Once the biochemical diagnosis of insulinoma has been established, imaging studies are performed, including non-invasive and invasive studies such as abdominal and intraoperative ultrasound, endosonography, arteriography, scan and MRI to determine the anatomical location of the tumor and the subsequent surgical plan. The choice of these modalities depends on availability and local radiological skills.

Abdominal ultrasound has low sensitivity that varies from 0% to 39%. The sensitivity of the ultrasound is affected by several factors, such as the doctor's experience, the weight of the patient, the

size and location of the tumor. Ultrasound findings generally show a very limited, homogeneous, hypoechoic nodule.<sup>7</sup>

Conventional computed tomography (CT) has sensitivity comparable to that of ultrasound, ranging from 22% to 43%. Multidetector computed tomography during intraarterial infusion of contrast medium (MDCT-IA) was evaluated in the study reported by Song P and collaborators for the location of insulinomas in 12 patients, who were surgically treated. Tumor location was successfully determined in 12/12 patients by MDCT-IA (100%) compared to 9/11 by magnetic resonance imaging (81.8%), 4/7 by CT (57.1%) and 7/12 by ultrasound-enhanced contrast (CEUS) (58.3%). Overall, MDCT-IA correctly located 100% of the lesions.<sup>8-10</sup>

Endoscopic ultrasound is considered by several authors as a reference test for preoperative insulinoma localization, with a sensitivity of about 80% to 93%. It can even detect small tumors in the order of 5 mm.<sup>7</sup> MRI has a sensitivity of 58% according to the study published by Mikkel Andreassen and collaborators.<sup>7</sup>

In the first case, the preoperative visualization of the lesion was achieved through endoscopic ultrasound and cholangioresonance, and in the second case, variability was evident in the studies of the location of the neuroendocrine tumor lesion. In both endosonography and initial magnetic resonance imaging of the second case, lesions in the neck of the pancreas were reported, and in second-time localization studies such as magnetic resonance imaging, no obvious pancreatic lesions were evident, Endosonography reported hypoechoic injury to the head of the pancreas. To confirm location in this case, intraoperative endosonography was decided. MDCT-IA was not performed despite its high sensitivity.<sup>8</sup>

Surgical resection is the treatment of choice and offers the only possibility of cure. Overall cure rates of 75-98% are reported after surgery, and prognosis depends on the stage of presentation and whether complete resection of the tumor was achieved. Recent guidelines for the management of gastroenteropancreatic neuroendocrine tumors suggest that surgery should be limited to hepatobiliary unit specialists.<sup>1</sup> In the two clinical cases presented in this article, surgical resolution was given with complete enucleation of neuroendocrine tumor. Both patients had post-surgical procedure improvement of neuroglucopenic, adrenergic and cholinergic signs and symptoms, showing both levels of fasting euglycemia, randomly and postprandial. Biopsy in both clinical cases was compatible with insulinoma characteristics, without malignancy data.

In conclusion, insulinoma is a rare pathology, delayed diagnosis can have catastrophic consequences for the patient such as permanent brain damage and death.<sup>9</sup> Readers and health workers are invited to suspect this pathology and thus carry out an appropriate clinical approach.

## Acknowledgements

None.

## Funding

None.

## Conflicts of Interest

All authors declare no conflict of interest.

## References

1. Tucker ON, Crotty PL, Conlon KC. The management of insulinoma. *Br J Surg.* 2006;93(3):264–275.
2. Gouta EL, Jerraya H, Dougaz W, et al. Endogenous hyperinsulinism: diagnostic and therapeutic difficulties. *Pan Afr Med J.* 2019;33:57.
3. Okabayashi T, Shima Y, Sumiyoshi T, et al. Diagnosis and management of insulinoma. *World J Gastroenterol.* 2013;19(6):829–837.
4. Chandrasekharappa SC, Guru SC, Manickam P, et al. Positional cloning of the gene for multiple endocrine neoplasia-type 1. *Science.* 1997;276(5311):404–407.
5. Cryer PE, Arbeláez AM. Hypoglycemia. *Williams Textbook of Endocrinology.* 14<sup>a</sup> (ed). España: Elsevier; 2020. p.1525–1551.
6. Cryer PE, Axelrod LL, Grossman AB, et al. Evaluation and Management of Adult Hypoglycemic Disorders: an Endocrine Society Clinical Practice Guideline. *J Clin Endocrinol Metab.* 2009;94(3):709–728.
7. Hadjkacem F, Kalthoum M, Ghorbel D, et al. Insulinome associé à une insuffisance corticotrope et un hypogonadisme hypergonadotrope: à propos d'une observation. *Pan Afr Med J.* 2019;34:32.
8. Pinzón A, Yucumá S. Hiperinsulinismo endógeno diagnosticado como epilepsia. *Revista colombiana de Endocrinología, Diabetes y Metabolismo.* 2016;3(1):51–55.
9. Giraldo J, Melo M, Abadía M, et al. Insulinoma del páncreas: informe de tres casos y discusión. *Rev Col Gastroenterol.* 2008;23(3):280–288.
10. Song P, Yan J, wang Y, Li X. Value of multidetector computed tomography during intra-arterial infusion of contrast medium for locating insulinomas. *Journal of International Medical Research.* 2020;48(3):1–8.
11. Alobaydun MA, Albayat AH, Al Nasif AA, et al. Pancreatic Insulinoma: Case Report of Rare Tumor. *Cureus.* 2019;11(12):e6408.